

Mechanisms of Left Ventricular Thrombus Formation in Heart Failure with Reduced Ejection Fraction (HFrEF): Insights from 2-D Speckle Tracking Echocardiography (2D-STE)

Dhruv Chawla MD, Tracy Hammonds PhD, Tadele Mengesha MA, Matt Umland RDCS, Khawaja Afzal Ammar MD, Vinay Thohan MD
Aurora Cardiovascular Services, Aurora St. Luke's Medical Center, Milwaukee, WI

BACKGROUND

HFrEF increases risk for LV thrombus formation

OBJECTIVE

To determine the role of 2D-STE associated with LV thrombus

METHODS

- Retrospectively identified patients with LVEF \leq 35%
 - LV thrombus (n=12)
 - No LV thrombus (n=36), matched (demographics and LVEF)
- Longitudinal strain: global and regional (18-segment model)

RESULTS

71% males of average age 62.7 ± 15.0 year

Table 1. Echocardiography and strain results. $p < 0.05$ are in bold.

	LV Thrombus	Control
LV ejection fraction (%)	22.7 ± 6.5	25.6 ± 6.8
LV end diastolic diameter (cm)	6.2 ± 1.1	5.5 ± 0.65
Regional strain		
Anterior	-4.4 ± 4.6	-6.6 ± 3.3
Inferior	-5.3 ± 3.9	-8.3 ± 4.1
Anterolateral	-7.1 ± 2.9	-7.3 ± 3.3
Inferolateral	-5.9 ± 5.1	-6.0 ± 3.6
Anteroseptal	-4.8 ± 4.0	-6.3 ± 4.8
Inferoseptal	-6.8 ± 2.3	-8.2 ± 3.3
Apex	-5.3 ± 4.4	-8.9 ± 4.0
Basal	-6.3 ± 4.0	-6.4 ± 4.0
Mid	-5.9 ± 2.8	-6.1 ± 3.1
LAD	-5.3 ± 3.4	-7.8 ± 3.4
LCx	-7.1 ± 3.1	-5.9 ± 3.7
RCA	-5.7 ± 4.0	-6.8 ± 3.5
Global longitudinal strain	-5.8 ± 2.7	-7.2 ± 2.7

Figure 1. Apical 2C view showing laminated LV thrombus (*) and 2D-STE strain abnormalities involving apex and inferior walls.

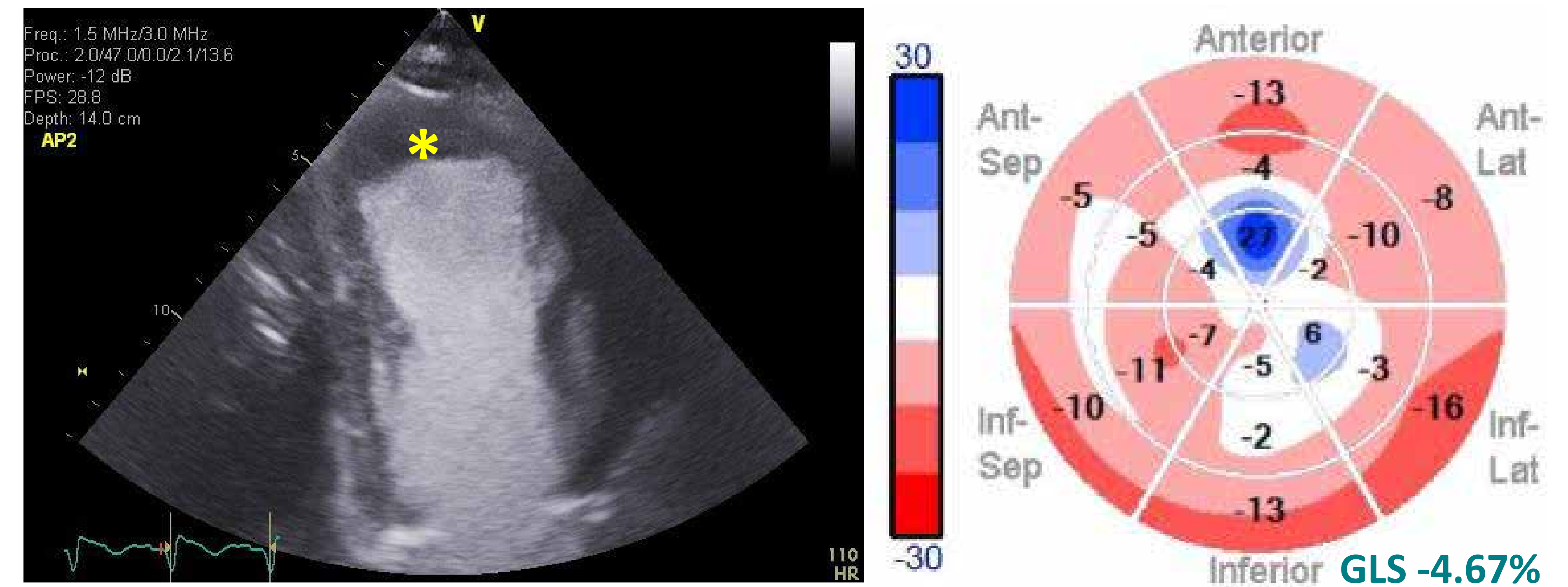
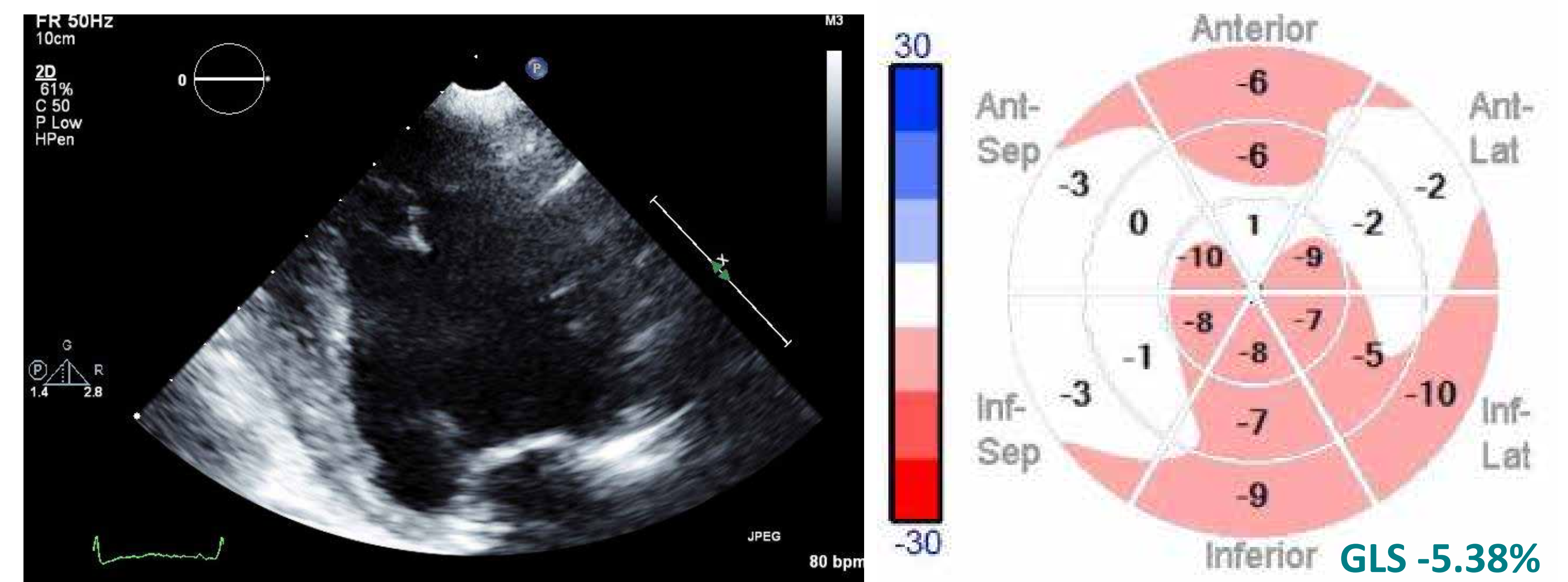


Figure 2. Apical 2C view showing no LV thrombus and 2D-STE strain showing sparing of apex and inferior walls.



CONCLUSIONS

Among patients with HFrEF, LV thrombus is associated with reduced longitudinal strain abnormalities in inferior and apical regions and in the left anterior descending territory.