

ANSA Pancreatica and Recurrent Acute Interstitial Pancreatitis – An Emerging Anatomic Variant

INTRODUCTION

Ansa pancreatica is a rare anatomic variant that has been associated with an increased risk of developing acute interstitial pancreatitis. We present a case of recurrent pancreatitis and ansa pancreatica diagnosed on endoscopic retrograde pancreatography (ERCP).

CLINICAL CASE

Patient is a 76-year-old female with history of gallstone pancreatitis status-post cholecystectomy who presented with epigastric pain and associated nausea and vomiting. Patient denied alcohol use. Patient's lipase was 14,406 unit/L and triglyceride level was normal. A computerized tomography with contrast revealed evidence of acute interstitial pancreatitis, a dilated pancreatic duct of 7mm, concern for pancreatic duct stone, and intra- and extra-hepatic duct dilation. Patient underwent MRI of the abdomen with and without contrast which revealed pancreatic duct dilation and a pancreatic duct stone. There was irregular calcific appearing abnormality on the right lateral margin of the pancreatic head near the minor papilla. There were no imaging findings to suggest a mass lesion and no choledocholithiasis. The patient was medically treated with intravenous fluids, diet was advanced, and the patient was discharged with plans for outpatient ERCP.

ERCP was performed two months after admission for acute pancreatitis. Pancreatic duct cannulation was achieved with a DASH sphincterotome and revealed ansa pancreatica with a dominant draining dorsal duct. A filling defect was apparent in the duct of Santorini and a pancreatic sphincterotomy was performed at the major papilla. The minor papilla was cannulated and stone debris was removed following a minor papillotomy. Patient tolerated the procedure without incident. To date, the patient has not had a recurrence of their acute pancreatitis.

DISCUSSION

We present a case of recurrent pancreatitis secondary to suspected ansa pancreatica. Ansa pancreatica is a rare anatomic variant, prevalence of 0.5-0.9%, described as an "S shaped loop" connecting the accessory pancreatic duct to the main pancreatic duct (1-6). There is an association between acute pancreatitis and ansa pancreatica, however, the mechanism is not well understood. This case highlights the anatomic variant specific to a dominant dorsal draining duct treated with a minor papillotomy and stone extraction. Further investigation is needed to address endoscopic cannulation of this anatomic variant and the association with acute pancreatitis.

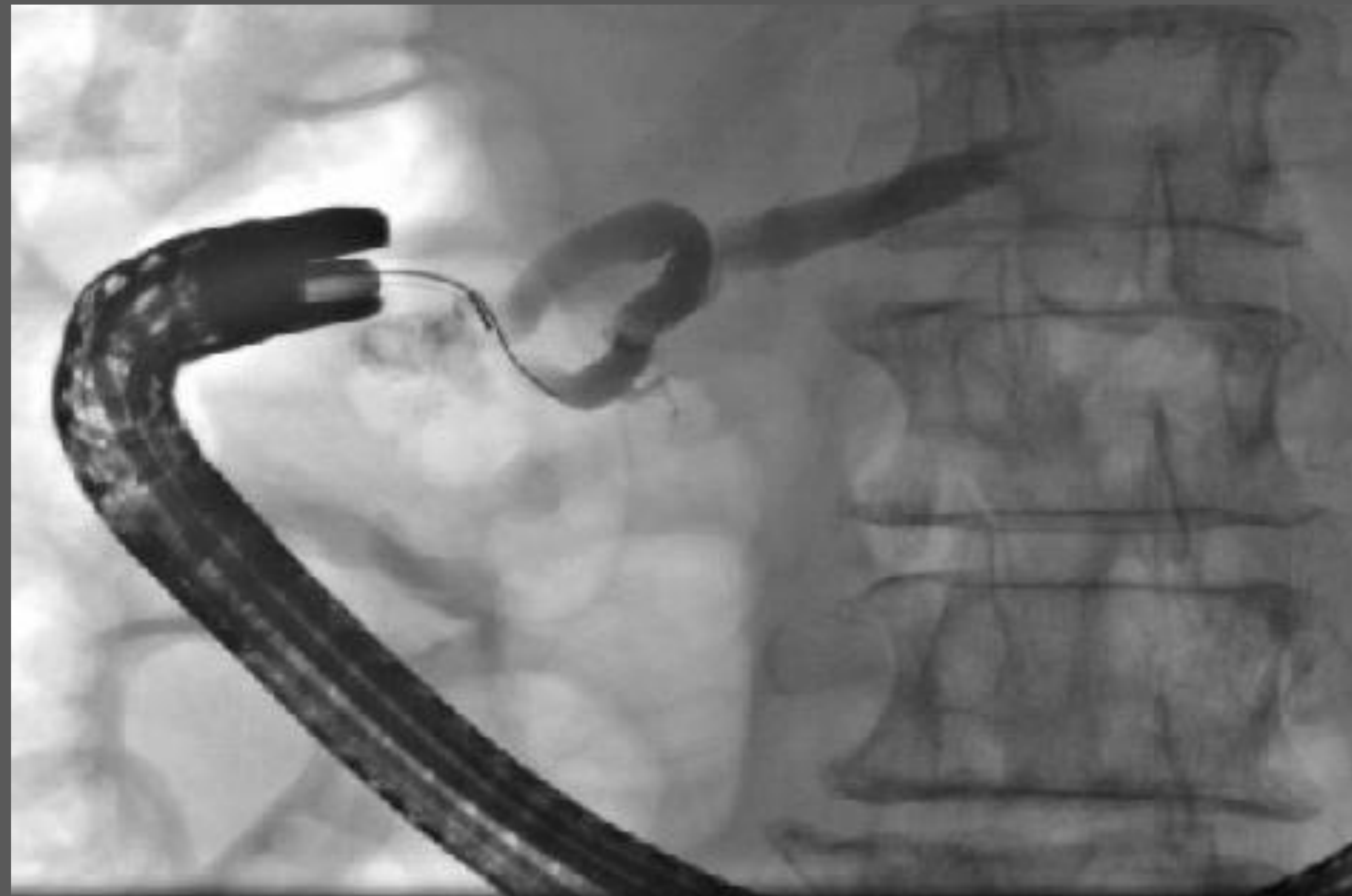

Figure 1. ERCP cholangiogram representing ANSA pancreatica.

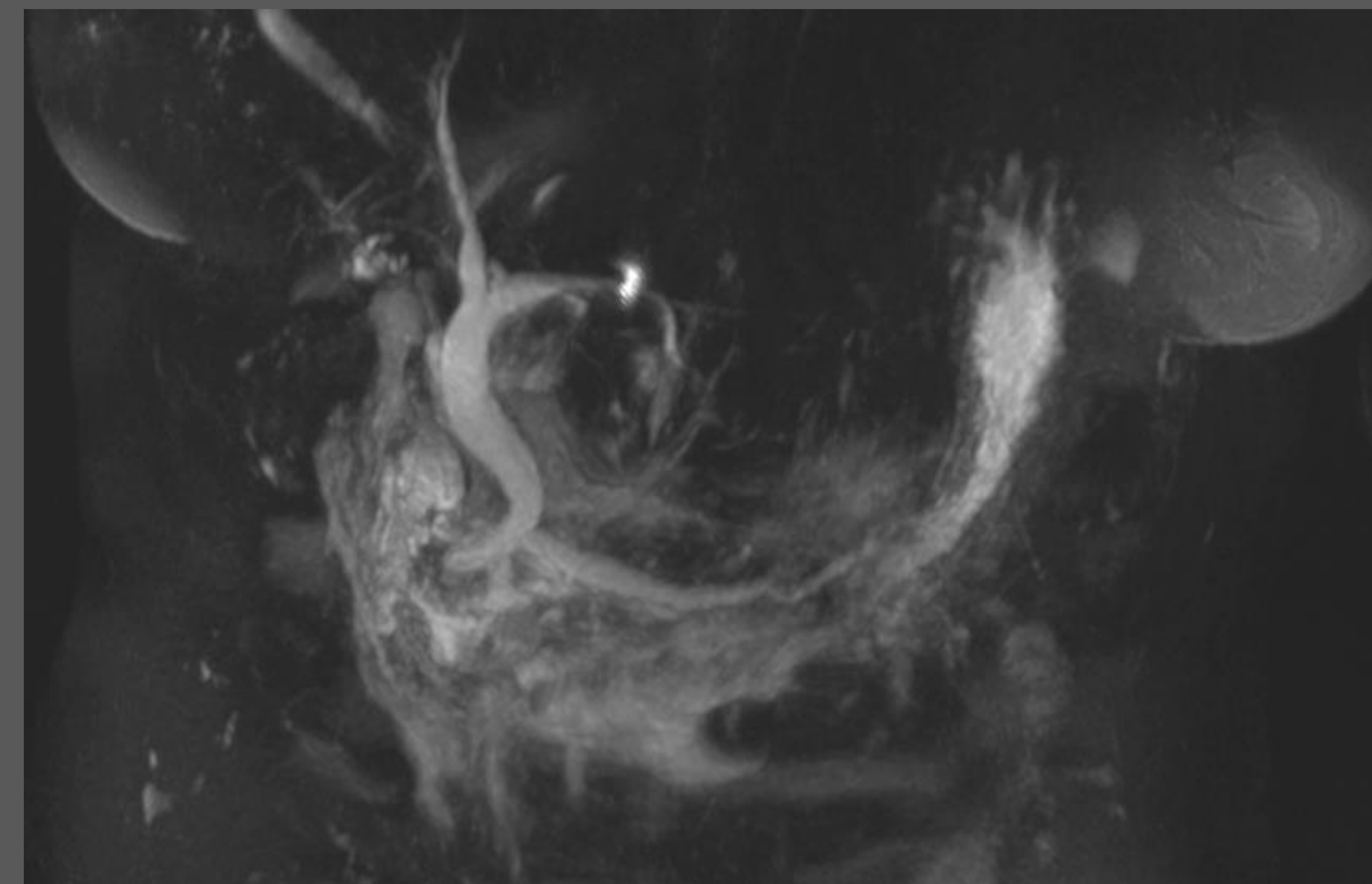


Figure 2. MRCP representing ANSA pancreatica.

REFERENCES

- 1, Shaikh DH, Alemam A, von Ende J, Ghazanfar H, Dev A, Balar B. Ansa Pancreatica, an Uncommon Cause of Acute, Recurrent Pancreatitis. *Case Rep Gastroenterol.* 2021;15(2):587-593. Published 2021 Jul 1. doi:10.1159/000516686
- 2, Ishii H, Arai K, Fukushima M, Maruoka Y, Hoshino M, Nakamura A, et al. Fusion variations of pancreatic ducts in patients with anomalous arrangement of pancreaticobiliary ductal system. *J Hepatobiliary Pancreat Surg.* 1998;5(3):327-32.
- 3, Adibelli ZH, Adatepe M, Imamoglu C, Esen OS, Erkan N, Yildirim M. Anatomic variations of the pancreatic duct and their relevance with the Cambridge classification system: MRCP findings of 1158 consecutive patients. *Radiol Oncol.* 2016;50(4):370-7.
- 4, Hayashi TY, Gondi W, Yoshikawa T, Hayashi N, Ohtomo K. Ansa pancreatica as a predisposing factor for recurrent acute pancreatitis. *World J Gastroenterol.* 2016;22(40):8940-8.5, Kosirog J, Boulay B, Yazici C. Ansa pancreatica, a rare cause of acute pancreatitis: clinical relevance and review of the literature. *JOP.* 2018; 19(6): 315- 320.
- 6, Ben Ismail I, Rebil S, Zenaidi H, Zoghalmi A. Acute pancreatitis secondary to ansa pancreatica: Two new cases and review of the literature. *Clin Case Rep.* 2022 Feb 1;10(2):e05381. doi: 10.1002/ccr3.5381. PMID: 35136610; PMCID: PMC8807883.